

Research Article

Lingual Node - A Prognostic Marker for Oral Tongue or Floor of the Mouth Carcinoma? - A Systematic Review

Sreejee Gopalakrishnan¹, A. Ramisz Rahman²

¹Lecturer, AB Shetty Memorial Institute of Dental Sciences, Mangaluru, Karnataka, India.

²Associate Consultant, Hannah Joseph Hospital, Madurai, Tamil Nadu, India.

DOI: <https://doi.org/10.24321/2456.141X.202201>

I N F O

Corresponding Author:

Sreejee Gopalakrishnan, AB Shetty Memorial Institute of Dental Sciences, Mangaluru, Karnataka, India.

E-mail Id:

sreejeegopalakrishnan@gmail.com

Orcid Id:

<https://orcid.org/0000-0002-2586-5524>

How to cite this article:

Gopalakrishnan S, Rahman R. Lingual Node - A Prognostic Marker for Oral Tongue or Floor of the Mouth Carcinoma? - A Systematic Review. J Adv Res Dent Oral Health. 2022;7(1&2):1-13.

Date of Submission: 2022-05-28

Date of Acceptance: 2022-06-28

A B S T R A C T

Background: Squamous Cell Carcinoma (SCC) of the tongue constitutes about 25% - 40% of oral carcinomas. Most often, treatment failure occurs as local and regional recurrences. Currently, the collection of Lingual Lymph Nodes (LLNs) that is located on the floor of the mouth has gained more attention. The lingual lymph nodes are inconstant para lingual intermediate nodes appearing along the course of the lymphatic vessels of the floor of the mouth. The aim was to assess if the presence of lingual node metastasis is a definitive prognostic marker for tongue and floor-the-mouth carcinoma through a systematic review.

Materials and Methods: Three electronic databases (PUBMED, Research Gate, and Google Scholar) were searched for patients diagnosed with the presence of Lingual lymph nodes who presented for the surgical treatment of oral tongue or floor of the mouth carcinoma. The search was performed on January 24th, 2020 with 214 abstracts reviewed for inclusion and 14 studies were included in this systematic review.

Results: Of the 241 abstracts reviewed, 45 manuscripts identified as eligible based on the abstracts and titles were searched for full text and analysed for inclusion. Fifteen manuscripts were relevant for inclusion in qualitative analysis.

Conclusion: The incidence of LLNs is linked with the pathological classification of SCC of the tongue and floor the of mouth. Additional studies are required to explore the optimal method of identifying the LLN before surgery.

Keywords: Squamous Cell Carcinoma, Oral Cancer, Lingual Node, Oral Carcinoma

Introduction

Squamous Cell Carcinoma (SCC) of the tongue constitute is about 25% - 40% of oral carcinomas. This along with the congeneric floor of mouth SCC (15% - 20%) can constitute

more than half of oral carcinomas when SCC of lips is excluded.¹²

The tongue has a complex lymphovascular system and musculature, which make it highly concomitant with cervical

metastasis. Currently, the collection of Lingual Lymph Nodes (LLNs) that is located on the floor of the mouth has gained more attention. According to numerous studies, the LLN may cause cervical metastasis in patients having SCC of the tongue and floor of mouth.¹²

Most commonly, treatment failure occurs as local and regional recurrences. The aim was to assess if the presence of lingual node metastasis is a definitive prognostic marker for tongue and floor of mouth carcinoma through a systematic review.

The objectives were to determine the presence of lingual lymph node, the presence of lingual node metastasis in Oral SCC, the prognostic value of lingual node metastasis in Oral SCC, whether to resect Lingual lymph node in addition to the traditional neck dissection in Oral SCC.

Methods

This manuscript followed the Preferred Reporting Items for Systematic Reviews and Meta-Analyses Protocols (PRISMA - P) for reporting a systematic review.

The PICO question was:

- Population: Patients diagnosed with the presence of Lingual lymph nodes who presented for the surgical treatment of oral tongue or floor of the mouth carcinoma
- Intervention: Lingual node resection
- Comparison: Traditional neck dissection and Neck dissection + compartmental surgery
- Outcomes: Decreased rate of recurrence, increased quality of life

Inclusion and Exclusion Criteria

Studies were limited to Case reports, Prospective and Retrospective cohort studies reporting the presence of Lingual lymph nodes in Participants diagnosed with oral tongue or floor-of the mouth carcinoma. The population included patients diagnosed with the presence of Lingual lymph nodes who presented for the surgical treatment of oral tongue or floor-of-the-mouth carcinoma.

Studies in the English language were only included and studies in language other than English were excluded. Studies on animals and cadavers were excluded.

There were no restrictions on the type of clinical setting. Studies at all levels of healthcare settings (such as primary, secondary, and tertiary healthcare) and those conducted in the community were included for maximum representation.

Search Methods for Identification of Studies

Three electronic databases (PUBMED, Research Gate, and Google Scholar) were searched using the strategies reported in Table 1. The search was performed on January 24th, 2020

with 214 abstracts reviewed for inclusion and 14 studies were included in this systematic review Table 1 Figure 1.

Table 1. Search Strategy

Search Terms (Medical Subject Headings)
“Lingual Node”
“Lingual Node” (key terms) AND “Oral Cancer” (all words)
“Lingual Node” (key terms) AND “Oral Cancer” (all words) AND “Tongue” (all words)
“Lingual Lymph node” AND “Tongue” OR “Floor of the mouth” OR “Oral Cancer”

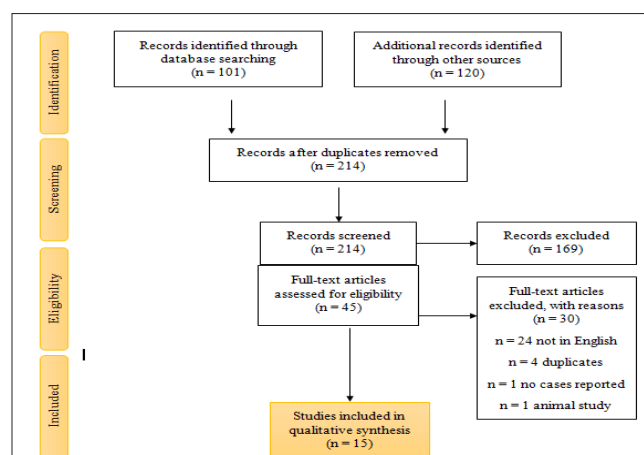


Figure 1. PRISMA Flow Diagram for Systematic Review

Data Collection and Analysis – Selection of Studies

Abstracts were initially reviewed to determine if the full-text article should be obtained. If the article fulfilled the criteria or if the authors were unable to decide regarding inclusion, a full-text article was obtained and evaluated Figure 1.

Results

Results of the Search

The initial search strategy yielded 214 unduplicated references including case reports and prospective and retrospective studies. These 214 references were assessed based in the abstracts and titles; these were reduced to 45 relevant manuscripts. Of those 169 references excluded, the main reasons for exclusion were: different conditions not oral carcinoma, abstract/conference proceedings, editorial/opinion.

Qualitative Analysis

All the 45 manuscripts identified as eligible based on the abstracts and titles were searched for full text and analysed for inclusion. Fifteen manuscripts were relevant

for inclusion in qualitative analysis (Table 2 shows the list of included studies with main characteristics). The main reasons for the exclusion of those 30 references were that they were not in English (n = 24), duplicates (n = 4), no cases reported (n = 1), and an animal study (n = 1).

Case Reports

Ozeki,¹ in 1984 reported 3 cases of carcinoma of the tongue with lingual node metastasis. The first case had a poorly differentiated squamous cell carcinoma (SCC) of the left lingual margin as well as the root of the tongue ($T_3N_3M_0$), treated by neo-adjuvant therapy (Bleomycin 240mg), hemiglossectomy and bilateral Radical Neck Dissection (RND). The Median Lingual Lymph Node (MLLN) was identified on surgical exploration and resected. The second case had a well-differentiated SCC of the right lingual margin ($T_1N_0M_0$) and Radium needles were inserted into the primary site and RND together with partial resection of the floor of the mouth was done after 4 months. One Lateral Lingual Lymph Node (LLLN) was identified on histopathologic examination. The third case also had a well-differentiated SCC of the right lingual margin ($T_2N_1M_0$) and a composite operation was performed. The Lateral Lingual Lymph Nodes (LLLN) were identified on histopathologic examination.

Dutton,² in 2002 reported a case of metastatic carcinoma of the mouth with lingual lymph node metastasis. The reported case had a well-differentiated SCC of the right lateral region of the tongue ($T_2N_0M_x$) for which right partial glossectomy and modified RND were performed and adjuvant radiotherapy was given. The sublingual node was identified on histopathologic examination.

Han,³ in 2007 reported a case of lingual lymph node metastasis of an SCC of the tongue. The case had a moderately differentiated SCC of the left margin of the tongue ($T_2N_0M_0$). Left partial glossectomy and modified RND were performed. Two lymph nodes of size 3 x 2 mm² and 2 x 2 mm² were identified above the sublingual gland histopathologically.

Umenda,⁴ in 2009 reported 2 cases of SCC of the floor of the mouth associated with lingual node metastasis. The first case had a well-differentiated SCC of the floor of the mouth ($T_3N_{2c}M_0$). The second case had a moderately differentiated SCC of the floor of the mouth ($T_2N_{2c}M_0$). In both cases, the tumour was resected and functional neck dissection was performed and the LLLN was identified surgically.

Ando,⁵ in 2009 reported a case of carcinoma of the tongue with metastasis to the lingual node. The reported case had a well-differentiated SCC of the left lateral margin of the tongue ($T_2N_2M_0$) for which subtotal glossectomy and bilateral neck dissection were performed. One lingual

node was identified along the lingual artery in the pre-operative Magnetic Resonance Imaging (MRI) scan, and two lingual nodes were identified on surgical exploration but on histopathologic examination three nodes were found around the sublingual gland and one along the lingual artery.

Saito,⁶ in 2010 identified an LLLN as the sentinel node on CT lymphography in a patient with well-differentiated SCC of the right lateral margin of the tongue (T_2N_0), treated by partial glossectomy.

Zhang,⁷ in 2011 reported 2 cases of SCC of the floor of the mouth with lingual lymph node metastasis. The first case was a well-differentiated SCC of the floor of the mouth, treated by Wide Local Excision (WLE) and Supraomohyoid Neck Dissection (SOHND). The lingual lymph node was identified in the pre-operative MRI and Positron Emission Tomography (PET) scans. The second case was a moderately differentiated SCC of the floor of the mouth, treated by composite resection of the tumour and Supraomohyoid Neck Dissection (SOHND). The lingual lymph node was identified histologically.

Tomblinson,⁸ in 2017 did a study to examine the prevalence of MLLN on imaging and its potential implications for oral cavity cancer staging. On reviewing 500 consecutive face-neck MRI scans, he identified 1 MLLN metastasis (of size - 1.4 x 1.0 x 1.1) from the lateral tongue carcinoma in the oral cancer group ($T_{4a}N_{2c}$) and 5 cases of MLLN in the control group.

Kaya,⁹ in 2017 reported a case of sublingual node metastasis of a moderately differentiated SCC of the floor of the mouth ($T_1N_0M_0$). The tumour was treated by WLE, bilateral sublingual gland resection in continuity with selective neck dissection. The lingual node was identified histologically in the sublingual region.

Nishio,¹⁰ in 2017 reported a case of lingual node metastasis of a well-differentiated SCC of the left lateral edge of the tongue ($T_1N_0M_0$). The tumour was surgically treated by partial glossectomy. The lingual node was identified in the genioglossus muscle, close to the hypoglossal nerve through pre-operative ultrasonography, MRI and PET scan.

Tiwari,¹¹ 2018 reported a case of SCC of the alveolus of the mandible ($T_2N_{2a}M_0$) with metastasis to a node near the sublingual gland. The tumour was surgically treated by Hemi-mandibulectomy and modified RND. The lingual node was identified on surgical exploration.

Jia,¹² in 2018 reported 5 cases of moderate to poorly differentiated SCC of the tongue (T_4N_0 , T_2N_0 , T_3N_0 , T_2N_1 , T_4N_1 - with no distant metastasis) with metastasis to the median and lateral lingual nodes. The nodes were identified on surgical exploration and confirmed histologically.

Table 2. Case Reports

Author	Place & Year	Title	Type of Study	Number of Cases	Staging of Lesion	Type and Location of the Lesion	Type of Treatment	Metastatic Lingual Lymph Node Size (mm)	Metastatic Lingual Lymph Node Group	Lingual Node Identification Method	Metastatic Cervical Nodes - Number	Metastatic Cervical Nodes - Group	Follow Up
Ozeki et al.	Japan, 1985	Metastasis to the lingual lymph node in carcinoma of the tongue	Case report	3	Case 1 - T ₃ N ₃ M ₀ Case 2 - T ₁ N ₀ M ₀ Case 3 - T ₂ N ₁ M ₀	Case 1 - Poorly differentiated SCC of left lingual margin and root of the tongue Case 2 - Well differentiated SCC of right lingual margin Case 3 - Well differentiated SCC of right lingual margin	Bleomycin 240mg - pull through operation, bilateral RND Radium needles, RND Composite operation	7 17 9	MLLN LLLN LLLN	Surgical exploration Histology Histology	20 4 1	Bilateral multiple metastasis Jugulo-carotid, Jugulo-omohyoid, Supra-clavicular Submental	9 months 5 years 10 years
Dutton et al.	USA, 2002	Metastatic cancer to the floor of mouth - The lingual lymph nodes	Case report	1	T ₂ N ₀ M _x	Well differentiated SCC of right lateral tongue	Right partial glossectomy, RND		Sublingual node	Histology	27		2 years
Han et al	China, 2007	Metastases to lingual lymph nodes for Squamous cell carcinoma of the tongue	Case report	1	T ₂ N ₀ M ₀	Moderately differentiated SCC of left margin of the tongue	Left partial glossectomy, Modified RND	3 x 2 mm & 2 x 2 mm	Above the sublingual gland	Histology		Level I & II	2 years

Umen- da et al.	Japan, 2009	Metastasis to the lingual lymph node in patient with Squa- mous cell carcinoma of the floor of the mouth: a report of two cases	Case report	2	Case 1 – T ₃ N _{2c} M ₀ Case 2 – T ₂ N _{2c} M ₀	Well differentiated SCC of floor of the mouth Moderately differ- entiated SCC of floor of the mouth	Tumour resec- tion & Bilateral functional neck dissec- tion Tumour resec- tion & Bilateral functional neck dissec- tion	LLLN LLLN	Surgical Surgical	4 2	Submen- tal, Upper Jugular Mid-Jug- ular	10 months 16 months
Ando et al.	Japan, 2009	Metastases to the lingual nodes in tongue can- cer: A pitfall in a conven- tional neck dissection	Case report	1	T ₂ N ₂ M ₀	Well differentiated SCC left lateral mar- gin of tongue	Subtotal glos- sectomy & bilateral neck dissection	Pre-op MRI-1 along lin- gual artery Surgical explora- tion-2 lin- gual nodes Histopa- thology-3 around sublingual gland, 1 along lin- gual artery	Pre-op MRI Surgical ex- ploration Histopathol- ogy	2	Subman- dibular, middle jugular chain	10 months

Saito et al.	Japan, 2010	The lingual lymph node identified as a sentinel node on CT lymphography in a patient with cNO squamous cell carcinoma of the tongue	Case report	1	T ₂ N ₀ M ₀	Well differentiated SCC of right lateral margin of tongue	Partial glossectomy		LLLN	CT lymphography	1	-	14 months
Zhang et al	China, 2011	Sublingual lymph node metastasis of early tongue cancer : report of two cases and review of literature	Case report	2	Case 1 – T ₂ N ₀ M ₀ Case 2 – T ₂ N ₀ M ₀	Case 1 - Well differentiated SCC of floor of the mouth Case 2 - Moderately differentiated SCC of floor of the mouth	Case 1 – WLE & SOHND, Case 2 – composite resection of tumour with SOHND		Lingual lymph-node of the floor of the mouth Lingual lymph-node of the floor of the mouth	MRI, PET Histology			Case 1-7months later metastasis to Level III node →MRI, PET →- SCC of floor of the mouth →WLE & RND - 3 months later died due to multi-organ failure Case 2- 2 years

Tomb-linson et al	USA, 2017	Median Lingual lymph nodes : Prevalence on imaging and potential implications for oral cavity cancer staging	Retro-spective study	1-in case group 5 – in control group	T _{4a} N _{2c} Non-cancer patients	Lateral tongue Squamous cell carcinoma	WLE + Bilateral RND	1.4 x 1.0 x 1.1 < 1 cm	MLLN-MLLN	PET, CT, Histology MRI	13	-	
Kaya et al	Turkey, 2017	Sublingual lymph node metastasis in early – stage floor of the mouth carcinoma	Case report	1	T ₁ N ₀ M ₀	Moderately differentiated SCC of floor of the mouth	WLE + Bilateral Sublingual gland resection in-continuity with selective neck dissection		Sublingual region	Histology			12 months
Nishio et al	Japan, 2017	Sonographic detection of a lingual node metastasis from early squamous cell cancer of the tongue	Case report	1	T ₁ N ₀ M ₀	Well differentiated SCC of left lateral edge of the tongue	Partial glossectomy		In genio-glossus muscle – close to hypoglossal nerve	Ultra-sonography, MRI, PET			9 months → recurrence – floor of the mouth → FNAC → MRI SOHND 5 years
Tiwari et al	India, 2018	Case report of metastatic presence of lingual lymph nodes in carcinoma alveolus of mandible	Case report	1	T ₂ N _{2a} M ₀	SCC of alveolus of mandible	Hemi-mandibulectomy & modified RND		Near sublingual gland	Surgical exploration			

Jia et al	China, 2018	Lingual lymph nodes in patients with Squamous cell carcinoma of the tongue and the floor of the mouth	Retrospective study	5	Case 1 – T ₄ N ₀ M ₀ Case 2 – T ₂ N ₀ M ₀ Case 3 – T ₃ N ₀ M ₀ Case 4 – T ₂ N ₁ M ₀ Case 5 – T ₄ N ₁ M ₀	Case 1 – Moderately differentiated SCC Case 2 – Moderately differentiated SCC Case 3 – Moderately differentiated SCC Case 4 – Poorly differentiated SCC Case 5 – Poorly differentiated SCC			Case 1 – MLLN Case 2 – LLLN Case 3 – MLLN Case 4 – LLLN Case 5 – LLLN	Surgical exploration, Histology		
Eguchi et al	Japan, 2019	Medial lingual lymph node metastasis in carcinoma of the tongue	Case report	1	T _{4a} N ₀ M ₀	SCC of right border of tongue	Hemi-glossectomy & SOHND	8 mm	MLLN	Surgical exploration, Histology		6 months → neck metastasis 8 months → modified RND 14 months → multiple distant metastasis → palliative radiation therapy 18 months → died

Fang et al	China, 2019	Value of lingual lymph node metastasis in patients with Squamous cell carcinoma of the tongue	Prospective study	33 (231-participants →58 - LLN →33 - had + LLN)	T ₃₋₄ N ₀ M ₀ or T ₃₋₄ N ₊ M ₀ or T ₂ N _x M ₀				28 - LLLN 2 - MLLN 3 - LLLN & MLLN	Surgical exploration, Histology			2 – 75 months
Ananian et al	Russia, 2015	Anatomic - histologic study of the floor of the mouth: the Lingual lymph nodes	Cadaver study	5 cadavers (of 21 cadavers)				1.4 – 8.7 mm (length) 0.8 – 7.5 mm (thickness)	4 – para-hyoid nodes 3- para-glandular nodes	Serial histologic microslides from specimens of blocks of the floor of mouth			

Eguchi¹³, in 2019 reported a case of SCC of the right border of the tongue (T_{4a}N₀M₀) with metastasis to the lingual node (size - 8mm). The tumour was treated by hemiglossectomy and SOHND. The lingual node was identified on surgical exploration and confirmed on histopathological examination.

Fang¹⁴, in 2019 prospectively studied the role of lingual node metastasis in patients with tongue carcinoma. Of the 231 patients analysed, 58 had lingual lymph nodes, of which 34 were positive for lingual node metastasis. Of the 33 cases, 28 had LLLN, 2 had MLLN and 3 had both LLLN and

MLLN. The nodes were identified on surgical exploration and confirmed histopathologically for metastasis.

Ananian¹⁵, in 2015 did a cadaveric study to identify the lingual lymphnodes. The lingual nodes were identified in 5 of the 21 cadavers studied. 4 parahyoid and 3 paraglandular nodes were identified through serial histological sections of the specimens from the floor of the mouth.

Of the 15 manuscripts, 10 papers analysed and confirmed the presence of lingual node metastasis histologically Table 3.

Table 3. Histologically Analysed Cases

Author	Place & Year	Staging of Lesion	Type and Location of the Lesion	Metastatic Lingual Lymph Node Group
Ozeki et al.	Japan, 1985	Case 2 - T ₁ N ₀ M ₀ Case 3 - T ₂ N ₁ M ₀	2nd Case - Well-differentiated SCC of right lingual margin 3rd Case - Well-differentiated SCC of right lingual margin	LLLN LLLN
Dutton et al.	USA, 2002	T ₂ N ₀ M _x	Well-differentiated SCC of right lateral tongue	Sublingual node
Han et al.	China, 2007	T ₂ N ₀ M ₀	Moderately differentiated SCC of the left margin of the tongue	Above the sublingual gland
Ando et al.	Japan, 2009	T ₂ N ₂ M ₀	Well-differentiated SCC left lateral margin of tongue	Pre-op MRI - 1 along the lingual artery Surgical exploration - 2 lingual nodes Histopathology – 3 around the sublingual gland, 1 along the lingual artery
Tomblinson et al.	USA, 2017	T _{4a} N _{2c}	Lateral tongue Squamous cell carcinoma	MLLN
Kaya et al.	Turkey, 2017	T ₁ N ₀ M ₀	Moderately differentiated SCC of floor of the mouth	Sublingual region
Jia et al.	China, 2018	Case 1 - T ₄ N ₀ M ₀ Case 2 - T ₂ N ₀ M ₀ Case 3 - T ₃ N ₀ M ₀ Case 4 - T ₂ N ₁ M ₀ Case 5 - T ₄ N ₁ M ₀	Case 1 - Moderately differentiated SCC Case 2 - Moderately differentiated SCC Case 3 - Moderately differentiated SCC Case 4 - Poorly differentiated SCC Case 5 - Poorly differentiated SCC	Case 1 - MLLN Case 2 - LLLN Case 3 - MLLN Case 4 - LLLN Case 5 - LLLN
Eguchi et al.	Japan, 2019	T _{4a} N ₀ M ₀	SCC of right border of tongue	MLLN

Fang et al.	China, 2019	T ₃₋₄ N ₀ M ₀ or T ₃₋₄ N ₊ M ₀ or T ₂ N _x M ₀		28 - LLLN 2 - MLLN 3 - LLLN & MLLN
Ananian et al.	Russia, 2015			4 - para-hyoid nodes 3- para-glandular nodes

Discussion

Metastasis of carcinoma of the oral cavity, especially of the tongue to the cervical lymph nodes is known to represent one of the major prognostic factors for the success or failure of the treatment. Although the modes of lymphatic spread to the neck in carcinoma of the tongue have been widely reported, still the presence of lingual lymph nodes appearing between the lingual structure and cervical lymph nodes has received only a little attention.¹ Occult lymph node metastases are an important prognostic factor, which indicates a reduction in the probability of controlling the disease and shortening survival.³

The tongue has a complex lymphovascular system and musculature, which make it highly concomitant with cervical metastasis when compared to the other sites of the oral cavity.¹²

The lingual lymph nodes are inconstant para lingual intermediate nodes appearing along the course of the lymphatic vessels of the floor of the mouth. The lingual lymph nodes, first identified in 1938 by Rouviere, were categorised as the in-transit nodes that appear rarely in lymphatic drainage pathways.⁶

Rouviere divided this unique cluster of nodes into two groups: lateral (LLLN) and Medial Lingual Lymph Nodes (MLLN). Groups of LLLN are present either laterally on the genioglossus muscle or on the hyoglossus muscle beside the lingual artery and vein, whereas the groups of MLLN are present on the central collecting vessels located beside the lingual septum.¹ This indicates that the LLLN and MLLN are located between the primary site and the neck and that they might be the first "Echelon nodes" in oral cancer patients.⁵ The superior limit of a cervical lymphadenectomy is anatomically demarcated anteriorly by the lower border of the mandible and surgically by the lingual nerve.²

The lingual lymph nodes are not considered in standard neck nodal classifications, and their unique location deep to the mylohyoid muscle distinguishes them from level I lymph nodes. As a result, lingual lymph nodes are not routinely included in neck dissections.⁸ The treatment failure of oral SCC usually results from local and regional recurrences.¹² Due to the close vicinity to the primary

tumour, lingual node metastases can be misinterpreted as a local recurrence.¹⁰

An animal study by Yang¹⁶ estimated the ability of indirect computer tomography and magnetic resonance lymphography (CT/MR-LG) for evaluating lingual sentinel lymph node (SLN) metastasis in a tongue carcinoma model. According to the study, the indirect CT/MR-LG along with Gd-Au PENPs helps in the metastatic diagnosis of lingual SLN in tongue cancer.¹⁶

According to Wu¹⁷ the injection of carbon nanoparticles can be used to track occult Lingual lymph nodes (LLNs) in early-stage tongue SCC. This method is simple as well as easy to use intra-operatively.¹⁷

The aim of this systematic review is to assess if the presence of lingual node metastasis is a definitive prognostic marker for carcinoma of the oral cavity and to determine whether to respect the Lingual lymph node in addition to the traditional neck dissection in Oral SCC.

The main goal of surgical oncology is to remove the primary tumour including a wide margin of normal tissue. The presently recognised custom is to remove the primary lesion along with a 1.5 - 2 cm circumferential macroscopic margin. Numerous modifications of neck dissection have been suggested and elective neck dissection increases the prognosis in early-stage T1-T2 oral tongue SCC. However, lingual lymph nodes (LLNs) are not routinely removed in a neck dissection as they are not categorised as conventional neck levels, especially for early-stage carcinomas.¹⁷

The presence of lingual nodes has changed the traditional neck dissection (discontinuous) to compartmental surgery (- continuity) which greatly improves the quality of life and reduces the recurrence rate. The advantage of compartmental resection is 3-fold:

- Complete removal of an involved muscle component which allows potential loco-regional micrometastasis
- This approach is a paradigm shift from circumferential to longitudinal resection that enables to performance of radical oncological resection
- Adequate pre-op imaging allows us to know the extent of the anatomical and functional defect and plan appropriate reconstruction

Conclusion

This review portrays that the incidence of LLNs is linked with the pathological classification of SCC of the tongue and floor of the mouth. Additional studies are required to find the ideal method of detecting the presence of LLN prior to surgery, and to know whether performing the LLN dissection can limit the rate of neck node metastasis, in addition, improve the survival rate in patients with SCC of tongue and floor of the mouth.

In patients with early SCC of the tongue and floor of the mouth, we recommend a wide-margin resection and inspection of LLNs. The decision of mylohyoid, genioglossal, and hyoglossal muscle preservation must be based on the pathological examination of the LLNs.

Acknowledgement

There is no conflict of interest between the authors. No funding sources.

Source of Funding: None

Conflict of Interest: None

References

1. Metastasis to the Lingual Lymph Node in Carcinoma of the Tongue Satoru Ozeki, Hideo Tashiro, Manabu Okamoto, Tsunehiko Matsushima, J. max.-fac. Surg, 1985;13:277-281. (URL : <https://www.sciencedirect.com/science/article/abs/pii/S0301050385800643>).
2. Metastatic cancer to the floor of mouth. The lingual lymph nodes, Jay M.Dutton, Scott M.Graham, Henry T.Hoffman, Head and Neck, 2002 (URL : <https://pubmed.ncbi.nlm.nih.gov/11933183/>).
3. Metastases to lingual lymph nodes for Squamous cell carcinoma of the tongue, Wei han, Xudong Yang, Xiaofeng Huang, Qingang Hu, Zhiyong Wang, BJOMS 2008;46:376-378. (URL : <https://www.sciencedirect.com/science/article/abs/pii/S0266435607004986>).
4. Metastasis to the lingual lymph node in patients with squamous cell carcinoma of the floor of the mouth a report of two cases, Masahiro Umeda, Tsutomu Minamikawa, Takashi Shigeta, Akiko Oguni, Tomoko Kataoka, Hidenori Takahashi, Yasuyuki Shibuya, and Takahide Komori, Kobe J. Med. Sci., 2009;55(3):E67-E72, (URL : <https://pubmed.ncbi.nlm.nih.gov/20847593/>).
5. Metastases to the lingual nodes in tongue cancer. A pitfall in a conventional neck dissection, Mizuo Ando, Masao Asai, Takayuki Ono, Yukihiro Nakanishi, Takahiro Asakaga, Tatsuya Yamasoba, Auris Nasus Larynx 37 2010;386–389. (URL : <https://pubmed.ncbi.nlm.nih.gov/19897329/>).
6. The lingual lymph node identified as a sentinel node on CT lymphography in a patient with cN0 squamous cell carcinoma of the tongue, M Saito, H Nishiyama, Y Oda, S Shingaki and T Hayashi, Dentomaxillofacial Radiology 2012;41:254–258. (URL : <https://pubmed.ncbi.nlm.nih.gov/22074865/>).
7. Sublingual lymph node metastasis of early tongue cancer report of two cases and review of literature, T.Zhang, R.A.Ord, W.I.Weil, J.Zhao, Int. J. Oral Maxillofac. Surg. 2011;40:597-600. (URL : https://www.researchgate.net/publication/49795085_Sublingual_lymph_node_metastasis_of_early_tongue_cancer_Report_of_two_cases_and_review_of_the_literature).
8. Median Lingual Lymph Nodes. Prevalence on Imaging and Potential Implications for Oral Cavity Cancer Staging, Courtney M. Tomblinson, Thomas H. Nagel, Leland S. Hu, Matthew A. Zarka, and Joseph M. Hoxworth, J Comput Assist Tomogr 2017;00.(URL: <https://europepmc.org/article/med/28099223>).
9. Sublingual Lymph Node Metastasis in Early-Stage Floor of the Mouth Carcinoma, İsa Kaya, Kerem Öztürk, Göksel Turhal, Turk Arch Otorhinolaryngol 2017;55: 177-9. (URL : <https://www.ncbi.nlm.nih.gov/pmc/articles/PMC5839527/>).
10. Sonographic detection of a lingual node metastasis from early squamous cell cancer of the tongue, Naoki Nishio, Yasushi Fujimoto, Mariko Hiramatsu, Yoko Yamamoto, Michihiko Sone, Journal of clinical Ultrasound, 2017;00(00). Month 2017 (URL : <https://pubmed.ncbi.nlm.nih.gov/28440859/>).
11. Case report of metastatic presence of lingual lymph nodes in carcinoma alveolus of mandible, Jacob John , Rahul Tiwari, Kaushal Charan Pahari, Philip Mathew, Heena Tiwari, International Journal of Oral Health Dentistry, 2018;4(2):121-123. (URL : <https://www.ijohd.org/article-details/7086>).
12. Lingual lymph nodes in patients with squamous cell carcinoma of the tongue and the floor of the mouth Jun Jia, Meng-qi Jia, Hai-xiao Zou, Head & Neck. 2018;1-6 (URL : <https://pubmed.ncbi.nlm.nih.gov/30051610/>).
13. Medial lingual lymph node metastasis in carcinoma of the tongue, Kohtaro Eguchi, Shigeo Kawai, Masayoshi Mukai, Hiroaki Nagashima, Satoshi Shirakura, Taro Sugimoto, Takahiro Asakage, Auris Nasus Larynx 2019. (URL : <https://pubmed.ncbi.nlm.nih.gov/30929928/>).
14. Value of Lingual Lymph Node Metastasis in Patients With Squamous Cell Carcinoma of the Tongue Qigen Fang, Peng Li, Jinxing Qi, Ruihua Luo, Defeng Chen, Xu Zhang, Laryngoscope 2019;00. (URL : <https://pubmed.ncbi.nlm.nih.gov/30861130/>).
15. Anatomic-histologic study of the floor of the mouth the lingual lymph nodes Sargis G. Ananian, Shalva R. Gvetadze, Konstantin D. Ilkaev, Valeria V. Mochalnikova, Georgiy O. Zayratiants, Vladimir A. Mkhitarov, Xin Yang, and Aleksandr M. Ciciashvili, Japanese Journal of Clinical Oncology. 2015;45(6):547-554. (URL : <https://>

- academic.oup.com/jjco/article/45/6/547/8142991).
16. Assessment of lingual sentinel lymph nodes metastases using dual-modal indirect CT/MR lymphography with gold-gadolinium-based nanoprobe in a tongue VX2 carcinoma model, Yue Yanga, Benqing Zhou, Jian Zhou, Xiangyang Shic, Yan Shad and Haitao Wu, *Acta Oto-laryngologica* 2018;138(8):727-733. (URL : <https://pubmed.ncbi.nlm.nih.gov/29513120/>).
 17. The use of carbon nanoparticles to track occult lingual lymph nodes in early-stage tongue squamous cell carcinoma, W.J. Wu, L. Zheng, J.G. Zhang, *Int. J. Oral Maxillofac. Surg.* 2019;48:1153-1155. (URL : <https://pubmed.ncbi.nlm.nih.gov/30876796/>).
 18. Compartmental surgery in tongue tumours. Description of a new surgical technique L, Calabrese G, Giugliano R, Bruschini M, Ansarin V, Navach E, Grosso B, Gibelli A, Ostuni F, Chiesa, *Acta otorhinolaryngologica italica* 2009;29:259-264. (URL : <https://www.ncbi.nlm.nih.gov/pmc/articles/PMC2821124/>).