

Case Report

# Interdental Pyogenic Granuloma with Ossification in a Pediatric Patient - A Rare Case Report and a Mini Literature Review

*Snigdha Gupta*<sup>1</sup>, *Anjulata K Gopinath*<sup>2</sup>, *Rashmi Dalal*<sup>3</sup>, *Shefaly Tandon*<sup>4</sup>,  
*Adhishree Singh Chib*<sup>5</sup>

<sup>1</sup>Lecturer, Department of Pedodontics and Preventive Dentistry, Inderprastha Dental College & Hospital, Uttar Pradesh, India.

<sup>2,3,4,5</sup>Ex Post Graduate student, Department of Pediatric and Preventive Dentistry, SGT University, Haryana, India.

DOI: <https://doi.org/10.24321/2456.141X.202203>

## I N F O

### Corresponding Author:

Snigdha Gupta, Department of Pedodontics and Preventive Dentistry, Inderprastha Dental College & Hospital, Uttar Pradesh, India.

### E-mail Id:

[snigdha.mds@gmail.com](mailto:snigdha.mds@gmail.com)

### Orcid Id:

<https://orcid.org/0000-0001-8022-380X>

### How to cite this article:

Gupta S, Gopinath AK, Dalal R, Tandon S, Chib AS. Interdental Pyogenic Granuloma with Ossification in a Pediatric Patient - A Rare Case Report and a Mini Literature Review. *J Adv Res Dent Oral Health*. 2022;7(3&4):6-10.

Date of Submission: 2022-11-10

Date of Acceptance: 2022-12-10

## A B S T R A C T

Pyogenic granuloma is an acquired benign proliferation of capillary blood vessels of the skin and oral cavity. Ossification in Pyogenic Granuloma is an uncommon pathology that is linked with the possible etiopathogenesis of irritation and foreign body reaction. A 12-year-old female patient reported a chief complaint of gingival growth in the upper right back teeth region, which was initially small in size and eventually grew to attain the present size in 2 months. Clinical examination revealed a painless pinkish pedunculated growth of approximately 1.5x1 centimetre superior-inferiorly and media-laterally. The histopathological examination of the excised lesion revealed an unlikely diagnosis of pyogenic granuloma with ossification. The rarity of the lesion can be attributed to the possible irritation to the tooth-supporting structures caused by rotation of the premolar. Also, ossification seen within the lesion adds to the dilemma. This case report presents a rare case of a gingival pyogenic granuloma in the interdental region adjacent to the rotated maxillary second premolar. It may have a possible etiology of trauma to interdental periodontal fibres caused by rotation of premolars due to disturbances during development.

**Keywords:** Benign, Children, Histopathology, Oral lesion, Vascular Neoplasm

## Introduction

Pyogenic granuloma is an acquired benign proliferation of capillary blood vessels of the skin and oral cavity.<sup>1</sup> Hüllien (1844) was the first one to report a case of Pyogenic Granuloma,<sup>2</sup> but the name was given later by Crocker (1903) and Hartzell (1904) thus it is called as Crocker and Hartzell's disease.<sup>3</sup> Histologically, due to the inflammatory nature and

presence of numerous blood vessels, Angelopus named it 'Hemangiomas Granuloma'. Occurrence of Pyogenic Granuloma in children is uncommon,<sup>4</sup> due to various associated etiological factors, its peak age of occurrence is the second and third decades with an incidence of 26.8%-32%.<sup>5</sup> The lesion has a female to the male predilection of 2:1 and usually presents as a painless swelling often causing

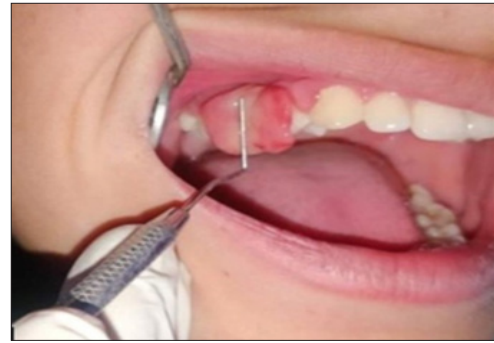
some interference in function or mastication. With the exact etiology still unknown it is often associated with factors such as local irritation, chronic trauma, poor oral hygiene, parafunctional habits, history of dental extraction, trauma while tooth brushing or overhanging dental restorations.<sup>5,6</sup> The most commonly involved site is the gingiva but the other probable sites can be the lips, tongue, palate and floor of the mouth.<sup>7</sup> Histopathological assessment is essential for the formulation of a confirmatory diagnosis. The present case is of a 12-year-old female patient reporting a rare interdental pedunculated pyogenic granuloma with ossification in relation to rotated premolar followed by a mini literature review.

### Case Report

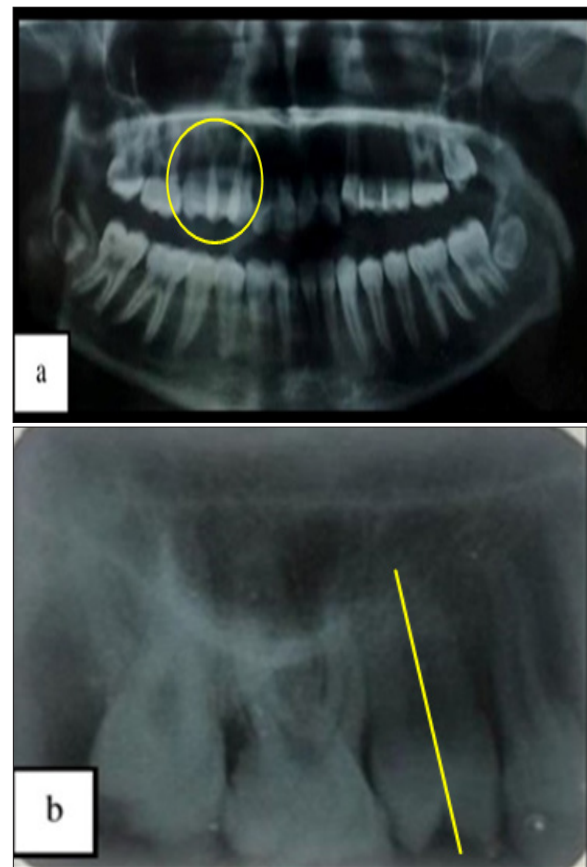
A 12-year-old female patient reported to the Department of Pediatric and Preventive Dentistry with the chief complaint of gingival growth in the upper right back teeth region. The patient noticed this growth in the gingiva of the maxillary posterior tooth region 2 months back. The growth was initially small in size and eventually grew to attain its present size. A detailed history was taken and no significant medical, dental or familial history was obtained, this was the patient's first dental visit. The patient was asked for any habit, allergy, traumatic brushing, long term medication however, a negative history was given. There was the absence of any extraction or restorations, or any local irritants like calculus or debris and the Oral Hygiene Index Score was good.

Extraoral examination showed no swelling or asymmetry and the lymph nodes were not palpable. Intraorally, hard tissue examination showed 28 permanent teeth with slight crowding in the maxillary arch and right second premolar rotated at 90 degrees. Soft tissue examination showed a solitary, painless, proliferative growth on the labial gingiva with respect to 14,15. The growth was pinkish, measuring approximately 1.5x1 centimeter media-laterally and superior-inferiorly. Palpation revealed a non-tender, soft, pedunculated growth with a stalk of approximately 4 mm attached to the buccal marginal gingival of the second premolar without perforation in the buccal cortex Figure 1. There were no caries, trauma, or mobility associated with the respective teeth.

Based on the clinical features a provisional diagnosis of Focal Fibrous hyperplasia and a differential diagnosis of Peripheral ossifying fibroma, Peripheral giant cell granuloma, Puberty gingivitis, Epulis granulomatosa & Pyogenic granuloma were made. Orthopantomogram and Intraoral periapical radiograph with respect to the tooth 14,15 was done. Radiographic findings revealed a rotated but healthy 2nd premolar with no changes in the periodontium and the periapical region Figure 2 (a), (b).



**Figure 1. The Lesion Extending from the Middle of First Premolar to Middle of First Molar**

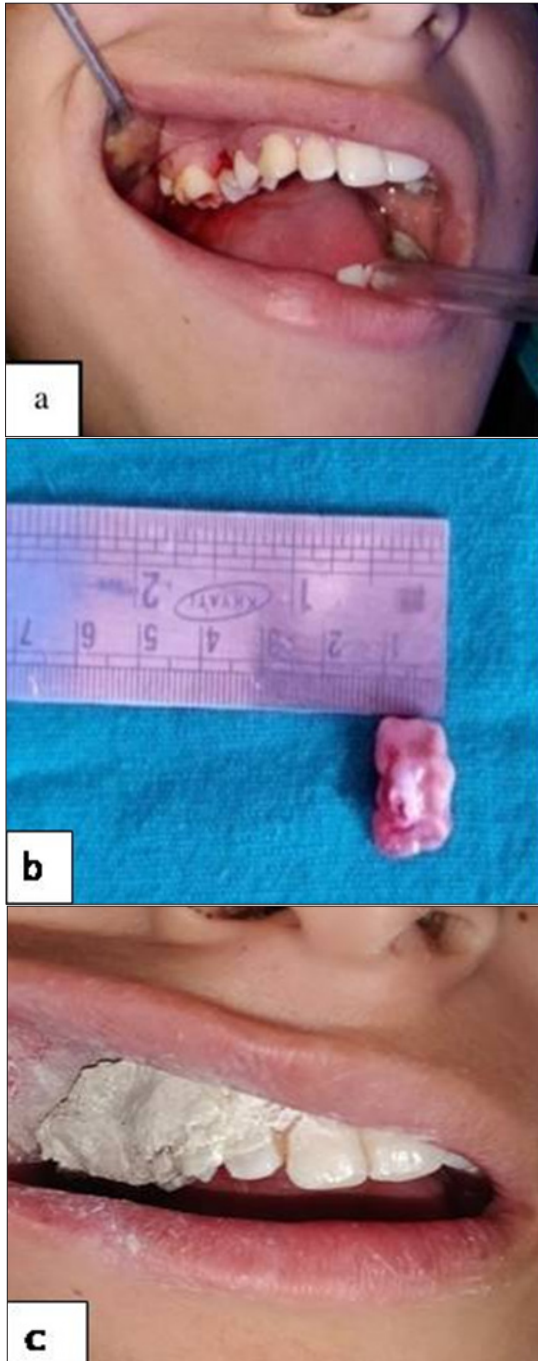


**Figure 2. Orthopantomogram and Intra Oral Periapical Radiograph w.r.t the Tooth 14,15 Showing a Healthy but Rotated Right Second Premolar with no Changes in the Periodontium and the Periapical Region**

Before the excision of the lesion, blood investigations were done which included Complete Blood Count, Bleeding Time, Clotting Time, Blood sugar, and Hb evaluation. The investigation reports were in the normal range and an excisional biopsy of the lesion was planned. The excision was performed using a 15 no BP blade and handle and after controlling the haemorrhage with a pressure pack Figure 3(a), a Zinc oxide Eugenol (ZoE) pack was given for 5 days. The tissue mass was measured to be 1.5 mesio laterally

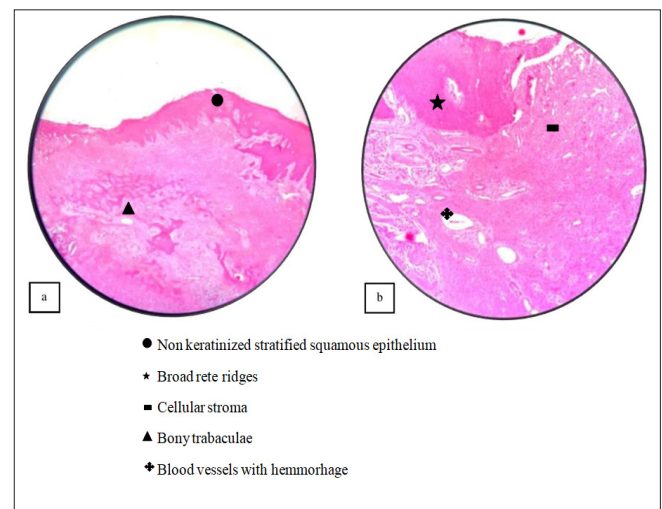
x1 cm superioinferiorly in dimension Figure 3b and further sent for histopathological investigation. Antibiotics and analgesics were prescribed for 3 days.

Histopathological examination of the section showed the presence of epithelium which is non keratinized stratified squamous showing hyperplasia with broad rete ridges.

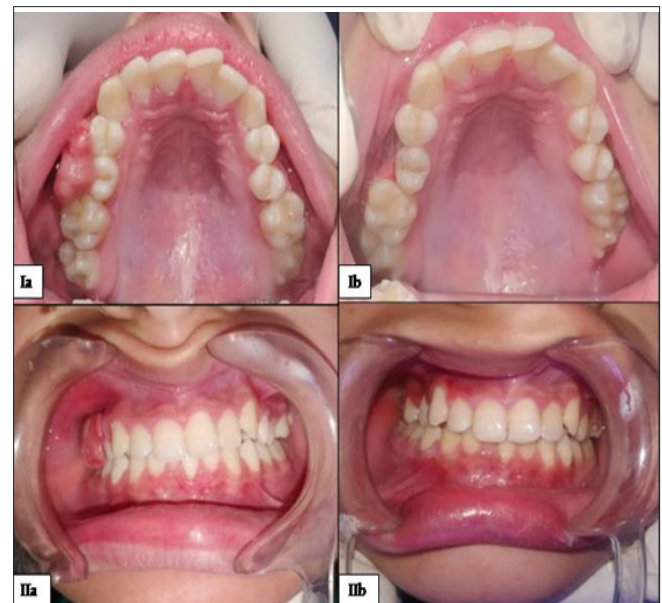

**Figure 3.** Post Operative after Surgical Excision, b) Excised Lesion Mass of Size 1.5 Mesio-Laterally Centimeters X 1 Centimeters Superior-Inferiorly c) Application of ZoE Pack for 1 Week

Connective tissues consist of cellular stroma with plenty of inflammatory cells and proliferating blood vessels. Areas of an eosinophilic trabecular pattern of thin bony trabeculae were seen in the connective tissue Table/ Figure 4 a,b. Correlating the clinical and histopathological findings, a final diagnosis of Pyogenic Granuloma with ossification was made. The patient was recalled after 5 days for ZoE pack removal, and to assess the healing, she was kept on a monthly recall for 6 months to check for any recurrence Figure 5. The patient was then referred to the Department of Orthodontics for further treatment and alignment of teeth.



**Figure 4.** Histopathological Slides a) Scanner View b) Magnification 4X



**Figure 5.** I-a) Occlusal View a) Pre Operative b) Post-operative; II-Frontal View a) Pre Operative b) Post Operative



## Discussion

In the present case, the exact etiology was unknown as detailed history revealed the absence of environmental factors, and examination showed the absence of local factors like calculus or debris and any caries, restoration, extraction at that site. However, trauma or disturbance during the development of rotated premolar must have contributed to the possible etiology of pyogenic granuloma.<sup>6</sup>

Pyogenic Granuloma was initially thought to be a botryomycotic infection- an infection in horses transmissible to humans. Although, it is now believed that it is not associated with infection. The term 'pyogenic granuloma' is a misnomer because the lesion does not contain pus, nor does it resemble a granuloma histologically.<sup>7</sup>

The most frequently involved site is the gingival and other sites are lip, tongue, buccal mucosa, and palate. In the present case, the lesion developed in the interdental area in relation to the rotated premolar which has not been reported prior. Radiographic findings are usually absent but in rare cases, localized alveolar bone resorption in large and long-standing gingival tumors can be seen.<sup>8</sup>

Surgical excision is the conventional treatment, other

options include cautery, laser, etc. After surgical excision of gingival lesions, curettage of the underlying tissue is recommended which was performed in the case. Pyogenic granuloma usually lacks malignant potential. Newer technique for removal of pyogenic granuloma reported is cryosurgery which is a safe, easy and inexpensive technique suited for out patient's clinic setting.<sup>9</sup> Nd:YAG, CO<sub>2</sub>, and flash lamp pulsed dye lasers have the advantages of minimal pain and invasiveness and the lack of need for suturing or packing thus have given successful results for the removal of Pyogenic Granuloma.<sup>10</sup> In the present case ossification seen along with the pyogenic granuloma is a rare finding and the patient therefore is still at a follow up to check for any recurrence.

A qualitative review was carried out through PubMed central for Pyogenic Granuloma in pediatric patients were recorded which resulted in 2187 articles, time constraint of 5 years (2016-2021) was applied which resulted in 103 articles. Abstracts of 103 articles were scanned, reviews and meta-analysis were excluded, any case report other than oral pyogenic granuloma were excluded and only those cases reported in children were selected. Finally, 4 case reports and case series were recorded for the probable etiology and their management Table 1.

**Table 1. Review of Pyogenic Granuloma in Pediatric Patients Due to Various Etiology in Last 5 Years**

Author, (Place) Year	Type	Age/Sex	Site	Probable Etiology	Management
Pisano M et al. (Italy) 2021 <sup>11</sup>	Case report	11/ Female	LOWER LIP	Unknown	Excised with a 980 nm Diode laser
Costello, L et al. (Dublin) 2019 <sup>12</sup>	Case report	12/Male	Hard palate	Unknown	Excisional biopsy
Peters, S. M. (Columbia) 2018 <sup>13</sup>	Case report	5/Female	Tongue	Injury by wooden Popsicle® stick	Excisional biopsy
Cheney-Peters, D., & Lund, T. C. (Minneapolis), 2016 <sup>14</sup>	Case series	5/male	left lateral tongue, dorsal tongue, bilateral buccal mucosa, and soft palate	Post bone marrow transplant and immunosuppressants	Excisional biopsy
		9/male	Right, middle dorsal part and ventral part of the tongue		Excisional biopsy
		11/female	Left lateral tongue		Excisional biopsy
		15/male	right, upper buccal mucosa		1) Chemical cautery, Excisional biopsy 2) Fibrillation; CO <sub>2</sub> laser
		6 days/ Male	Right sided tongue		Excisional biopsy

## Conclusion

This case report presents a rare case of a gingival pyogenic granuloma in the interdental region of a rotated premolar with possible etiology of the trauma of interdental periodontal fibres caused by rotation of premolar due to some disturbances during its development. Since such cases are rare, they must be reported in the literature to create knowledge and understanding about the uncommon possible etiology associated with pyogenic granuloma and associated ossification with the same.

## Acknowledgement

We would like to thank the Department of Oral Pathology and Histology and their Head Of Department for the biopsy report and images.

**Source of Funding:** None

**Conflict of Interest:** None

## References

1. Sachdeva SK. Extralingival pyogenic granuloma an unusual clinical presentation. *Journal of dentistry*. 2015;16(3):282.
2. Hullihen SP. Case of Aneurism by Anastomosis of the Superior Maxillare. *The American journal of dental science*. 1844;4(3):160.
3. Hartzell MB. Granuloma pyogenicum. *J Cutan Dis Syph*. 1904;22:520-5.
4. Al-Khateeb T, Ababneh K. Oral pyogenic granuloma in Jordanians a retrospective analysis of 108 cases. *Journal of oral and maxillofacial surgery*. 2003;1;61(11):1285-8.
5. Krishnapillai R, Punnoose K, Angadi PV, Koneru A. Oral pyogenic granuloma-a review of 215 cases in a South Indian Teaching Hospital, Karnataka, over a period of 20 years. *Oral and maxillofacial surgery*. 2012;16(3):305-9.
6. Patil K, Mahima VG, Lahari K. Extralingival pyogenic granuloma. *Indian journal of dental research*. 2006;1;17(4):199.
7. Neville BW, Damm DD, Allen C, Chi AC. *Oral and maxillofacial pathology*. Elsevier Health Sciences. 2015;13.
8. Burket LW, Greenberg MS, Glick M. *Burket's oral medicine diagnosis & treatment*. PmphBc Decker. 2003.
9. Ishida MD CE, Ramos-e-Silva MD, PhD M. Cryosurgery in oral lesions. *International journal of dermatology*. 1998;37(4):283-5.
10. Khandpur S, Sharma VK. Successful treatment of multiple gingival pyogenic granulomas with pulsed-dye laser. *Indian J Dermatol Venereol Leprol*. 2008;74:275-7.
11. Pisano M, Sammartino P, Di Vittorio L, Iandolo A, Caggiano M, Roghi M, Bizzoca ME, Muzio LL. Use of Diode Laser for Surgical Removal of Pyogenic Granuloma of the Lower Lip in a Pediatric Patient. *A Case Report. American Journal of Case Reports*. 2021;19;22.
12. Costello L, Huston M. An unusual presentation of a pyogenic granuloma in a paediatric patient. *Journal of paediatrics and child health*. 2019;55(4):486-7.
13. Peters SM, Koslovsky DA, Yoon AJ, Philipone EM. Pyogenic granuloma in the tongue in a five year old a case report. *The Journal of clinical pediatric dentistry*. 2018;42(5):383.
14. Cheney-Peters D, Lund TC. Oral pyogenic granuloma after bone marrow transplant in the pediatric/adolescent population. Report of 5 Cases. *Journal of pediatric hematology/oncology*. 2016;1;38(7):570-3.