

Short Article

Familial Swyer Syndrome

Alka Tajne

Vibrant Nursing College, Surat, Gujarat, India.

DOI: <https://doi.org/10.24321/2348.2133.202108>

I N F O

E-mail Id:

alkatajne@gmail.com

Orcid Id:

<https://orcid.org/0000-0003-0333-2556>

How to cite this article:

Tajne A. Familial Swyer Syndrome. Ind J Holist Nurs. 2021;12(1):23-25.

Date of Submission: 2021-02-23

Date of Acceptance: 2021-03-10

I N T R O D U C T I O N

Swyer syndrome is a rare condition in which the reproductive organs of an individual are affected along with his/ her sexual development. Sexual development is mainly determined by an individual's chromosomes. However, it is not commensurate with the affected individual's chromosomal make-up in Swyer syndrome.

The human body has 46 chromosomes in each cell. 23rd pair of chromosome have X and Y chromosomes which are also called sex chromosomes. They help to determine whether a person will develop male or female characteristics.

Definition

Swyer syndrome is a rare genetic entity that is characterised by the failure of sex glands to develop in the presence of normal 46, XY karyotype. There are rapid and early degenerative changes in gonads that appear in adults as "streak gonads" consisting mainly of fibrous tissue and ovarian stroma, and secondary sexual characteristics are not developed.

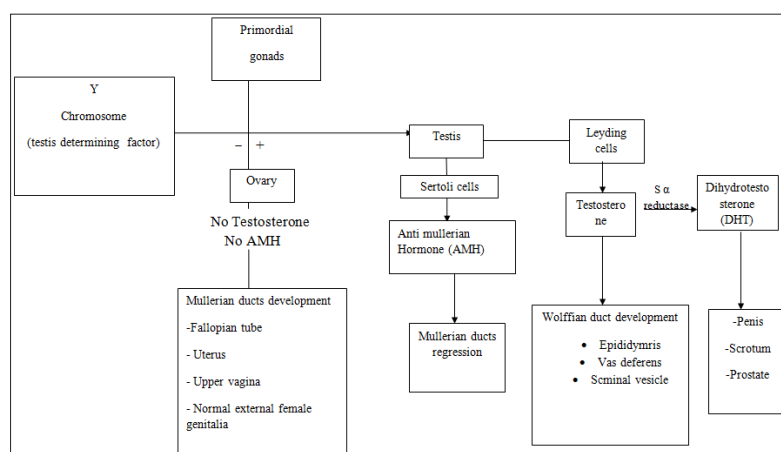


Figure 1. Simplified Model of Sexual Differentiation and the Development of External and Internal Genitalia

Aetiology

1. Foetal endocrinology/ Disorder in gonadal development
 - 46, XX DSD (masculinised females)
 - Congenital adrenal hyperplasia

- Elevated androgens in maternal circulation
 - Aromatase (P450 among) deficiency
- 46, XY DSD (incompletely masculinised males)
 - Androgen insensitivity syndromes
 - 5-alpha-reductase deficiency
 - Enzymatic testosterone biosynthesis defect
 - Gonadotropin resistant testis
 - AMH-deficiency

Clinical Features

- Ambiguous genitalia in males
- Lack of pubertal development
- Amenorrhoea in females
- Salt-wasting in both genders because of 3-β-hydroxysteroid dehydrogenase deficiency, hypertrophied clitoris
- Infertility
- Skeletal disorder (sometimes) due to P450 deficiency

Diagnosis

- Prenatal
 - CAH is autosomal recessive
 - Detection of elevated amniotic fluid level
 - CVS
- Postnatal
 - Ambiguous genitalia not palpable
 - 17OHP blood
 - Plasma renin activity
- Urinary 17 Ketosteroid

Management Prenatal

Glucocorticoid administration to mother in order to suppress the foetal adrenal hormone (inj. dexamethasone).

Postnatal

Medical

- Hydrocortisone 10 mg/ day
- Prednisolone 3.5-5 mg/m² surface area

Surgical

- General Consideration
- Patients should be genetically female

Surgical Correction after Medical HT

- Parents should be given counselling regarding treatment

Surgical Procedure

- Reduction of clitoris size
- Division of labioscrotal folds
- Initiation of hormone replacement therapy during the period of adolescence that helps in inducing

menstruation along with the development of female secondary sex characteristics such as breast

- Replacement therapy will help to reduce bone density
- As a woman with Swyer syndrome does not produce eggs, they can get pregnant with donated eggs or embryos
- Give psychological support to parents with proper counselling and evidence-based practice

Conclusion

Familial Swyer syndrome is a gonadal dysgenesis disorder that affects the growth and development of sexual organs which leads to disturbed sexual development in individuals. This can be treated with timely intervention with counselling. I have seen 3 patients of such condition during my Masters degree in Wadia Pediatric Hospital, Mumbai. Parents are very eager to know the gender of the baby after birth. This condition can be very painful and unbearable for them. In this condition, parents should be counselled with a detailed treatment plan. Psychological support is also highly essential in such a situation.

Conflict of Interest: None

References

- Datta DC. Textbook of obstetrics. 8th ed. New Delhi: Jaypee Brothers Medical Publishers; 2015.
- Kumari N, Sharma S, Gupta P. A textbook of midwifery and gynecological nursing. India: S Vikas and Company India; 2017.
- Jacob A. A comprehensive textbook of midwifery & gynecological nursing. 5th ed. Jaypee Brothers Medical Publishers; 2019. [Google Scholar]
- Banoth M, Naru RR, Inamdar MB, Chowhan AK. Familial Swyer syndrome: a rare genetic entity. Gynecol Endocrinol. 2018;34(5):389-93. [PubMed] [Google Scholar]
- Da Silva Rios S, Mazzaro Monteiro IC, Santos LG, Caldas NG, Chen AC, Chen JR, Silva HL. A case of Swyer syndrome associated with advanced gonadal dysgerminoma involving long survival. Case Rep Oncol. 2015;8:179-84. [PubMed] [Google Scholar]
- Kempe A, Engels H, Schubert R, Meindl A, van der Ven K, Plath H, Rhiem K, Schwanitz G, Schmutzler RK. Familial ovarian dysgerminomas (Swyer syndrome) in females associated with 46 XY-karyotype. Gynecol Endocrinol. 2002;16(2):107-11. [PubMed] [Google Scholar]
- Han Y, Wang Y, Li Q, Dai S, He A, Wang E. Dysgerminoma in a case of 46, XY pure gonadal dysgenesis (Swyer syndrome): a case report. Diagn Pathol. 2011;6:84. [PubMed] [Google Scholar]
- Iqbal MB, Mushtaq I, Kambale T, Dey I. Swyer syndrome (46XY pure gonadal dysgenesis) presenting with

- dysgerminoma. Arch Med Health Sci. 2019;7(2):248-50. [Google Scholar]
9. Brosnan PG, Lewandowski RC, Toguri AG, Payer AF, Meyer WJ. A new familial syndrome of 46,XY gonadal dysgenesis with anomalies of ectodermal and mesodermal structures. J Pediatr. 1980;97(4):586-90. [PubMed] [Google Scholar]
 10. Khare J, Deb P, Srivastava P, Reddy BH. Swyer syndrome: the gender swayer?; Alex J Med. 2017;53(2):197-200. [Google Scholar]
 11. Bagci B, Bisgin A, Karauzum SB, Trak B, Luleci G. Complete gonadal dysgenesis 46,XY (Swyer syndrome) in two sisters and their mother's maternal aunt with a female phenotype. Fertil Steril. 2011;95(5):1786.e1-3. [PubMed] [Google Scholar]
 12. Machado C, Pereira A, Cruz JM, Cadilhe A, Silva A, Pereira A. A novel SRY nonsense mutation in a case of Swyer syndrome. J Pediatr Neonatal Indiv Med. 2014;3(1). [Google Scholar]
 13. Patnayak R, Suresh V, Jena A, Rajagopal G, Vijayalakshmi B, Reddy AP, Rukumangadha M, Sachan A. Swyer syndrome: a case report with literature review. J Nepal Med Assoc. 2012;52(186):72-4. [Google Scholar]
 14. Shetty DP, Arumugam M, Kadandale JS, Kumari S. Swyer syndrome in phenotypic female with 46,XY karyotype-case series. J Clin Diag Res. 2018;12(11):1-3. [Google Scholar]
 15. Yadav P, Khaladkar S, Gujrati A. Imaging findings in dysgerminoma in a case of 46 XY, complete gonadal dysgenesis (swyer syndrome). J Clin Diagn Res. 2016;10(9). [Google Scholar]
 16. Babu R, Shah U. Gender identity disorder (GID) in adolescents and adults with differences of sex development (DSD): a systematic review and meta-analysis. J Pediatr Urol. 2021;17(1):39-47. [PubMed] [Google Scholar]
 17. Al Jurayyan NA. Disorders of sex development: diagnostic approaches and management options – an Islamic perspective. Malays J Med Sci. 2011;18:4-12. [PubMed] [Google Scholar]