

Iron and Silver Contributions to Systemic Toxicity in Albino Rats *In Vivo*

Tugbobo OS¹, Idowu KS², Abegunde SM³, Odutuga AA⁴

^{1,2,3}Department of Science Technology, Federal Polytechnic, Ado-Ekiti, Nigeria.

⁴Department of Chemical Sciences, Joseph Ayo Babalola University, Ikeji-Arakeji, Nigeria.

Abstract

Indiscriminate exposure of man to iron and silver toxicity through a long-term ingestion of contaminated food, utensils and water coupled with its health challenges has been widely reported. This study examined the effect of iron (II) sulphate (2.5 mg/kg body weight) and silver nitrate (1.5 mg/kg body weight) fed to albino rats consecutively alone and simultaneously for two weeks (14-days). Control animals were fed with distilled water. Hematological and biochemical analyses as well as histopathological examination of kidney and liver tissues were monitored. The findings indicate that there was significant ($P < 0.05$) decrease in the values of hematological parameters while the histopathology of rats fed with the metals showed grossly hemorrhagic cells riddled with lesion of varying degrees. Besides, there was significant ($P < 0.05$) difference in the values obtained for alkaline phosphatase (ALP), aspartate aminotransferase (AST) and acid phosphatase (ACP) when compared with control. The results suggest development of microcytosis, hepatotoxicity and nephrotoxicity induced by iron sulphate and silver nitrate simultaneously.

Keywords: Iron sulphate, Phosphatase, Silver nitrate, Transferase, Toxicity

Introduction

Occupational and environmental co-exposure to iron and silver as well as other heavy metals have been documented.⁸ Such exposure usually occurs via ingestion of contaminated food and water most especially in the industrialized areas.¹ These include contaminated water from rusted pipes, herbal medicine products, tobacco smoke and dust, metal alloyed plates, welding, smelting and recycling of electrical tools as well as electroplating.⁶ Heavy metals are clastogens causing oxidative burst in the exposed individuals leading to tissue damage.² Damage to DNA and other body tissues by these metals is likely to be a major cause of cancer and genetic birth defects and perhaps contribute to aging and cardiovascular diseases.¹² In addition, chronic exposure to heavy metals especially iron is associated with microcytic anemia, neuropathy, diarrhea, hypertension and renal failure.³ Hence, this study was designed to investigate and evaluate the interaction and synergy of the toxic effects of iron and silver in rats.

Materials and Methods

Chemicals

Iron (II) sulphate ($\text{FeSO}_4 \cdot 7\text{H}_2\text{O}$, Aldrich Chemicals Co. Inc., U.S.A) and silver nitrate AgNO_3 , Sigma Chemicals Co. U.S.A) were dissolved in distilled water using 3-drops of acetic acid to dissolve iron sulphate precipitate before being administered at a dose of 2.5 mg/kg body weight and 1.5 mg/kg silver nitrate respectively.⁹ All other reagents and chemicals were of analytical grade and were obtained from Sigma Chemical Co. U.S.A.

Experimental Animals

Twenty-four (24) male albino rats weighing between $120 \pm 5\text{g}$ were purchased from Agricultural Research Institute, Moore Plantation, Apata, Ibadan, Nigeria. The animals were randomly distributed into cages and allowed to acclimatize for 14-days. They were fed with rat pellet and water *ad libitum* under room temperature of $25 \pm 2^\circ\text{C}$ and 12 hours alternating day and night cycles.

Corresponding Author: Abegunde SM, Department of Science Technology, Federal Polytechnic, Ado-Ekiti, Nigeria.

E-mail Id: abegundes@gmail.com

Orcid Id: <https://orcid.org/0000-0002-6688-5230>

How to cite this article: Tugbobo OS, Idowu KS, Abegunde SM et al. Iron and Silver Contributions to Systemic Toxicity in Albino Rats *In Vivo*. *J Adv Res BioChem Pharma* 2018; 1(3&4): 1-3.

Experimental Design

The rats were divided into four groups; A, B, C and D. Animals in group A were administered distilled water only, B and C animals were treated with iron sulphate (2.5 mg/kg) and silver nitrate (1.5 mg/kg) respectively, while iron sulphate (2.5 mg/kg) and silver nitrate (1.5 mg/kg) were administered simultaneously into animals in group D. All animals from each group were sacrificed 48 hours after the last dose under light ether anesthesia.

Hematological Assay

Blood samples were collected through cardiac puncture and immediately transferred into tubes containing EDTA for analysis of hematological parameters such as hemoglobin, total red blood cells (RBC), packed cell volume (PCV), total white blood cells (W.B.C.) using hematology analyzer Sysmex XS800i Sysmex Corporation, USA using (Latner, 1943; Cosner, 1950 and Schrolder and Jason, 1995) methods respectively.

Biochemical Assay

The biochemical parameters in the whole blood were

assayed using the metabolic panel on an automated chemistry analyzer (Piccolo Blood Chemistry Analyzer, Abaxis, Union City, CA, USA) which include; urea nitrogen, glucose, alkaline phosphatase (ALP), aspartate aminotransferase (AST) and acid phosphatase (ACP) using methods of Sazsz (1969); Rietzman S and Frankel S and Wright DJ et al.^{10,13}

Histopathological Assay

The tissue specimen from the control and test groups were fixed in 10% buffered formalin for 48hr. The formalin fixed samples were stained with haematoxylin – eosin. The sections were examined microscopically for changes in histopathological architecture.⁵

Statistical Analysis

Results were expressed as mean ± standard deviation (SD) and analyzed by one-way analysis of variance (ANOVA) and Duncan multiple range tests. The results obtained were compared with that of the control group. P values <0.05 were considered significant.

Results

Table 1. Hematological parameters of rats following administration of iron and silver salts

Parameters	Group A	Group B	Group C	Group D
White blood cell count (x10 ⁹ /L)	5.76±1.02 ^a	7.80±0.49 ^{ab}	9.25±1.77 ^{bc}	10.60±1.85 ^c
Hemoglobin (g/dl)	12.53±4.38 ^a	5.78±2.74 ^b	5.73±1.30 ^b	3.70±8.24 ^c
Red blood cell (x10 ¹² /L)	4.63±0.59 ^a	1.38±2.02 ^b	0.70±1.70 ^b	0.30±0.03 ^{ab}
Packed cell volume (%)	32.67±2.09 ^a	18.50±5.02 ^{ab}	20.00±4.41 ^{ab}	13.50±4.95 ^c

Results are expressed as means ± standard deviation. Values along the horizontal row with different superscripts indicate significant difference at (P <0.05).

Table 2. Biochemical parameters of rats following administration of iron and silver salts

Parameters	Group A	Group B	Group C	Group D
Urea nitrogen (mg/dl)	5.76±1.02 ^a	7.80±0.49 ^{ab}	9.25±1.77 ^{bc}	10.60±1.85 ^c
Glucose (mg/dl)	23.16±5.60 ^a	37.33±10.07 ^b	37.76±4.16 ^b	47.90±8.51 ^c
Alkaline phosphatase (U/L)	127.63±4.01 ^a	130.38±2.02 ^b	135.70±1.70 ^b	149.30±0.03 ^c
Aspartate transaminase (U/L)	219.00±16.52 ^a	221.00±6.56 ^a	222.33±24.17 ^a	234.77±9.83 ^a
Acid phosphatase (U/L)	167.67±2.09 ^a	170.50±5.02 ^a	172.00±25.75 ^a	172.16±38.81 ^a

Results are expressed as means ± standard deviation. Values along the horizontal row with different superscripts indicate significant difference at (P < 0.05).

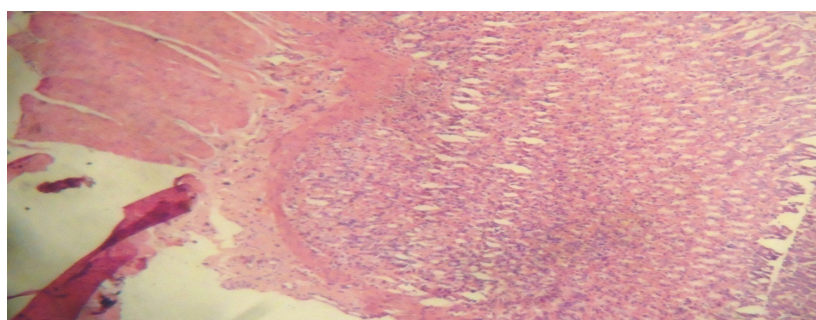


Figure 1. Histopathological architecture of rat kidney treated with distilled water only

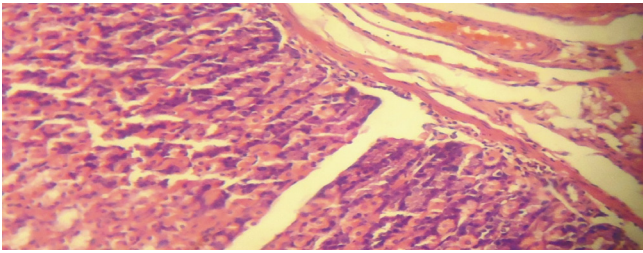


Figure 2. Histopathological architecture of rat kidney treated with iron and silver

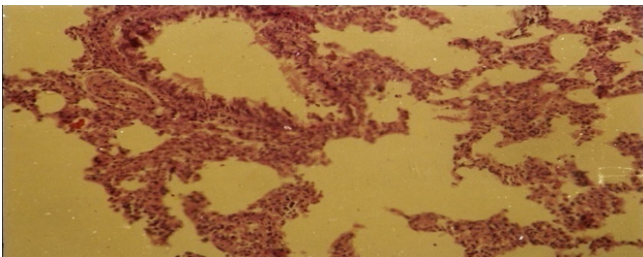


Figure 3. Histopathological architecture of rat liver treated with iron and silver

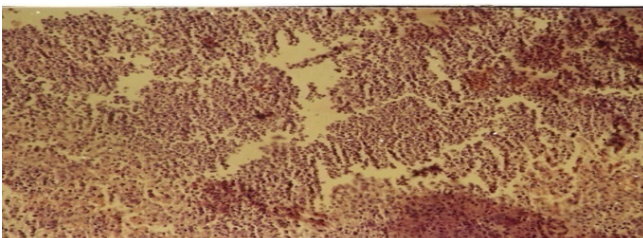

Figure 4. Histopathological architecture of rat liver treated with distilled water

Discussion

This study was designed primarily to assess the effect of co-exposure to iron and silver in rats. The results of the study clearly indicate development of microcytic anemia in the test animals in group D. Mycrocytosis could develop due to significant ($P < 0.05$) reduction in the values of hemoglobin, erythrocytes and packed cell volume of rats in group D compared to control. This could be as a result of hematologic disorder caused by binding of iron and silver to thiol group of protein in the body which consequently impair the heme-synthetase enzymes; delta-aminolaevulinic acid dehydratase and ferro chelatase that play vital role in heme synthesis.⁷ Also, it has been reported that decrease in serum protein could result from massive destruction of red blood cells.⁴ Besides, the severe inhibition of red blood cells production by these metals consequently reduces the ATP energy needed for the kidney ultra-filtration process and this perhaps is responsible for significant ($P < 0.05$) increase in values of urea nitrogen and glucose in group D animals compared to control. This could possibly result in condition such as aminoaciduria, glucosuria which are symptoms of nephrotoxicity. The results obtained from the assessment of serum activities of ALP, AST and ACP show the toxicity of co-exposure of iron and silver. The elevated levels of ALP and AST in group D animals compared to control indicate

organ dysfunction where the enzymes leaked into the extracellular fluid. This serves as biochemical symptoms of cytolysis.¹¹ In addition, the elevated levels of ACP and ALP could as well be attributed to labialization of biliary duct and *de novo* synthesis of the enzyme molecules in liver and kidney. The result from histopathology of rats fed with the metals in plates 2 and 3 (kidney and liver) respectively show grossly hemorrhagic cells riddled with lesions of varying degrees while that of control animals were normal. Hence, co-exposure to iron and silver is harmful and deleterious to life.

Conflict of Interest: None

References

1. Abegunde SM, Dada EB, Adelaja OI. Assessment of heavy metals distribution and contamination in atmospheric dust from major roads in Ado-Ekiti, Ekiti State using pollution indices. *International Journal of New Technology and Research* 2018; 4(4): 34-40.
2. Brautbar MD. Neurobehavioral changes, hypertension and kidney diseases. *JAMA* 2005; 253: 530-4.
3. Clarkson TW, Woolf AD. Metal toxicity in central nervous system. *Int J Occup Med Environ Health* 2001; 14(3): 312-20.
4. Das SK, Nair RC. Lipid peroxidation of normal and sickled erythrocytes. *Br J Heamatol* 1980; 44(1): 87-92.
5. Griffin WT, Fahim MS. Histopathological method on tissue atrophy. *JAMA* 2002; 103: 331-6.
6. Lambert T, Lane DA. Iron, arsenic and PAH in soil and house dust. *Environ. Health Perspect* 2004; 112(1): 39-41.
7. Leonard A. Metals and their deleterious effects in the body. *Biochem Biophys Acta* 1991; 1288: 179-88.
8. Nehez M, Lorenez R, Desi I. Simultaneous action of cypermethrin with cadmium and lead on rat chromosomes in subchronic administration. *Ecotoxicol Environ Saf* 2000; 45: 55-60.
9. Preston RJ, Dean BS, Galloway S et al. Mammalian hematologic and bone marrow assay. *Mutat Res* 1987; 189: 157-65.
10. Rietzman S, Frankel S. Calometric method for the determination of aspartate amino transferase and alanine amino transferase. *Am J Clin Pathol* 1957; 28: 56-63.
11. Schmidt SH, Schmidt G. Biochemical symptoms of rat liver cytolysis. *Am J Clin Pathol* 1979; 45: 101-109.
12. Tugbobo OS, Oloyede OI, Adewale O. Protection by garlic against lead-induced oxidative stress and genetic birth defects. *Journals of Oxidants and Antioxidants Medical Sciences* 2014; 3(1): 79-82.
13. Wright DJ, Leathwood PD, Plummer DT. Enzymes in rat urine; acid and alkaline phosphatases. *Enzymology* 1972; 42(6): 317-327.

Date of Submission: 2018-11-01

Date of Acceptance: 2018-12-12