

Case Report

# Xanthogranulomatous Oophoritis: A Rare and Forgotten Entity

Jyoti Mishra<sup>1</sup>, Salony Mittal<sup>1</sup>, Samriddhi Allahabadi<sup>3</sup>

<sup>1</sup>Professor, <sup>2</sup>Associate Professor, <sup>3</sup>Junior Resident, Department of Pathology, School of Medical Sciences and Research, Sharda Hospital, Greater Noida, Uttar Pradesh.

DOI: <https://doi.org/10.24321/2454.8642.202203>

## I N F O

### Corresponding Author:

Jyoti Mishra, Department of Pathology, School of Medical Sciences and Research, Sharda Hospital, Greater Noida, Uttar Pradesh.

### E-mail Id:

drm714@gmail.com

### Orcid Id:

<https://orcid.org/0000-0003-1574-3475>

### How to cite this article:

Mishra J, Mittal S, Allahabadi S. Xanthogranulomatous Oophoritis: A Rare and Forgotten Entity. *Rec Adv Path Lab Med.* 2022;8(1&2)4-6.

Date of Submission: 2022-04-12

Date of Acceptance: 2022-04-30

## A B S T R A C T

Xanthogranulomatous oophoritis is a rare condition characterized by chronic inflammation and destruction of ovarian tissue. This case report describes a 25-year-old woman who presented with symptoms of bleeding, abdominal pain, and fever. Imaging revealed a tubo-ovarian mass, and during surgery, a pus-filled mass adhered to the right ovary was excised. Histopathological examination confirmed xanthogranulomatous oophoritis, and the pus culture showed the presence of coagulase-negative *Staphylococcus aureus*. This condition is often mistaken for ovarian malignancy and requires surgical removal of the affected ovary. Antibiotic therapy has not been successful in reducing the ovarian mass.

**Keywords:** Xanthogranulomatous Oophoritis, Surgical Excision, Malignancy, Antibiotic Therapy

## Introduction

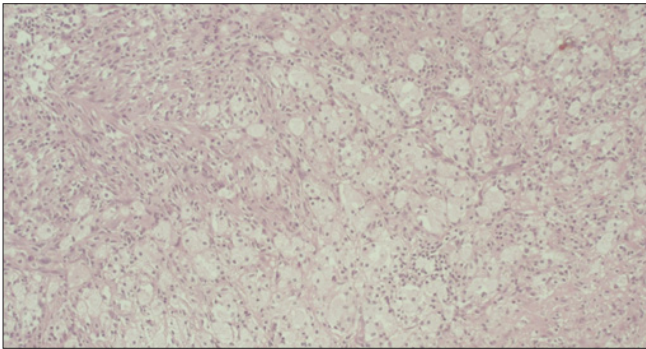
Xanthogranulomatous inflammation is a type of chronic inflammation in which the normal tissue of affected organs is destroyed. The commonly affected organs are kidneys, gall bladder, stomach, bone, urinary bladder, anorectum, and male and female genital tracts. It is characterised by the presence of numerous lipid-laden macrophages admixed with lymphocytes, plasma cells, neutrophils, and multinucleated giant cells.

## Case Report

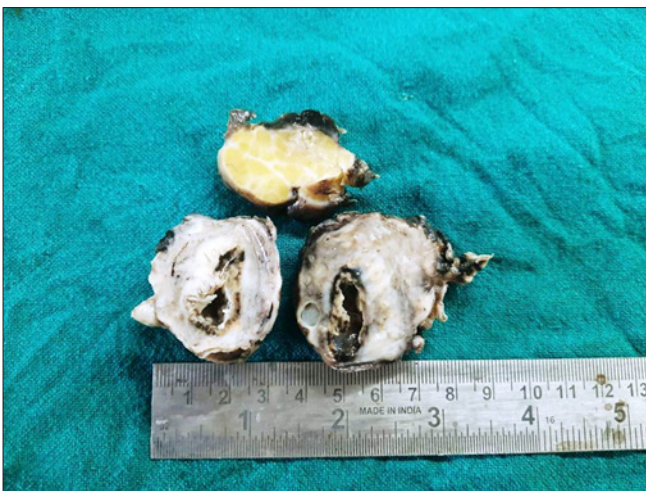A 25-year-old lady P0A1 presented to the gynaecology outpatient department with a history of off-and-on bleeding, abdominal pain, and high-grade fever. She had a history of intrauterine death of 5 months gestation with spontaneous expulsion two and a half months back. Per abdominal examination revealed a mass about 16-20 weeks in size. On

per vaginum, a right ovarian mass was felt measuring 10 x 8 cm. Ultrasound and MRI showed a unilateral tubo-ovarian mass measuring 7 x 5 cm. Intraoperatively, a pus-filled mass was seen in the right ovary that was adherent to the small intestine. The mass was excised and sent for histopathology evaluation. On gross examination, a single globular grey-brown soft tissue piece was received measuring 5 x 4 x 2 cm which was externally congested. Cut surface showed grey-white to brown, yellowish areas (Figure 1). Solid areas were also seen with a cyst measuring 2 x 1 cm. Also, received in the same container, lying separately, was a fibrofatty tissue piece measuring 4 x 3 cm. On microscopy, sections showed ovarian stroma with a collection of foamy macrophages (Figure 2), lymphocytes, and plasma cells along with abundant haemorrhage. Adjacent areas showed blood vessels and granulation tissue. Histomorphological features were conclusive of xanthogranulomatous oophoritis. The

pus was sent for culture and sensitivity which showed growth of coagulase-negative *Staphylococcus aureus*.



**Figure 1. Cut Surface of Ovary - Pale Yellow Appearance**



**Figure 2. Hematoxylin and Eosin Stained Section revealing many Scattered Foam Cells in Ovary (40x)**

## Discussion

Xanthogranulomatous oophoritis is a rare entity. It was first described by Kunakemakorn et al.<sup>1</sup> in the report of inflammatory pseudotumour of pelvis. To the best of our knowledge, to date, only 15 cases of female genital tract with xanthogranulomatous inflammation have been reported which include 7 cases of unilateral ovary, 5 cases of unilateral fallopian tube, 1 case of bilateral fallopian tube involvement, and only 2 cases of ovary and fallopian tube showing simultaneous involvement. Various theories of aetiopathogenesis of xanthogranulomatous oophoritis are established like infection, endometriosis, metabolic defects, and drugs. The most widely accepted theory is of infection. *Escherichia coli*, *Bacteroides fragilis*, and *Proteus vulgaris* are the commonly found aetiological agents. Rarely, *Staphylococcus aureus* and *Salmonella typhi* can be implicated in the pathogenesis of xanthogranulomatous oophoritis. Punia et al.<sup>2</sup> reported a case of xanthogranulomatous oophoritis and salpingitis as late sequelae of inadequately treated staphylococcal pelvic inflammatory disease. Shukla et al.<sup>3</sup> have reported a case of

xanthogranulomatous oophoritis associated with primary infertility and endometriosis. Premature ovarian failure as a rare sequela of xanthogranulomatous inflammation has also been reported. Cases of xanthogranulomatous inflammation of ovary with ovarian hemangioma,<sup>4,5</sup> secondary to diverticulitis,<sup>6</sup> as an unusual cause of tubo-ovarian abscess,<sup>7</sup> associated with endometriosis and uterine leiomyoma,<sup>8</sup> associated with diabetes mellitus<sup>10</sup>, secondary to talcum powder,<sup>11</sup> presenting as an unusual complication of typhoid,<sup>12</sup> and following uterine artery embolization<sup>13</sup> have been reported. Our case revealed positive growth of *Staphylococcus aureus*. Xanthogranulomatous oophoritis may mimic malignancy on radiology. These patients usually present with fever, abdominal lump, pain, menorrhagia, anaemia, and anorexia. Grossly, the affected ovary is enlarged with a yellowish appearance and partially cystic areas due to necrosis. Differential diagnosis includes tuberculosis, fungal infections, and malakoplakia. The presence of Michaelis-Gutmann bodies differentiates malakoplakia from xanthogranulomatous oophoritis. Xanthogranulomatous oophoritis can be easily confused with ovarian malignancy clinically, radiologically as well as pathologically. Immunohistochemistry helps in differentiating but is seldom required in the presence of characteristic histopathological features. The treatment of choice for xanthogranulomatous salpingo-oophoritis is salpingo-oophorectomy as done in this case. Antibiotic therapy has been attempted, but so far it has not succeeded in reducing ovarian mass. This rare entity can pose to be a diagnostic dilemma for a radiologist, hence its histopathological features need to be emphasised.

## Conclusion

Xanthogranulomatous oophoritis is clinically important due to its resemblance to ovarian malignancy, necessitating surgical intervention for accurate diagnosis and treatment. Histopathologically, it is significant for its characteristic features differentiating it from other inflammatory conditions.

**Conflict of Interest:** None

## References

1. Kunakemakorn P, Ontai G, Balin H. Pelvic inflammatory pseudotumor: a case report. Am J Obstet Gynecol. 1976;126(2):286-7. [PubMed] [Google Scholar]
2. Punia RS, Aggarwal R, Amanjit, Mohan H. Xanthogranulomatous oophoritis and salpingitis: late sequelae of inadequately treated staphylococcal PID. Indian J Pathol Microbiol. 2003;46:80-1. [PubMed] [Google Scholar]
3. Shukla S, Pujani M, Singh SK, Pujani M. Xanthogranulomatous oophoritis associated with primary infertility and endometriosis. Indian J Pathol

- Microbiol. 2010;53:197-8. [PubMed] [Google Scholar]
4. Chechia A, Bahri N, Felah R, Khaireddine A, Sakouhi M, Zakhama A. [Tubo-ovarian xanthogranulomatous inflammation. Report of a case]. *Tunis Med.* 1999;77:593-6. French. [PubMed] [Google Scholar]
  5. Shashikala K, Sharmila PS, Sushma TA, Francis P. Ovarian haemangioma with synchronous xanthogranulomatous inflammation - a rare pathological finding. *Int J Health Sci Res.* 2013;5:116-9.
  6. Altanis S, Raweily E, Katesmark M. Xanthogranulomatous endometritis and oophoritis secondary to diverticulitis. A rare cause of postmenopausal bleeding. *J Obstet Gynaecol.* 2007;27:746-7. [PubMed] [Google Scholar]
  7. Kim SH, Kim SH, Yang DM, Kim KA. Unusual causes of tubo-ovarian abscess: CT and MR imaging findings. *Radiographics.* 2004;24:1575-89. [PubMed] [Google Scholar]
  8. Abeyesundara PK, Padumadasa GS, Tissera WG, Wijesinghe PS. Xanthogranulomatous salpingitis and oophoritis associated with endometriosis and uterine leiomyoma presenting as intestinal obstruction. *J Obstet Gynaecol Res.* 2012;38:1115-7. [PubMed] [Google Scholar]
  9. Yener N, Ilter E, Midi A. Xanthogranulomatous salpingitis as a rare pathologic aspect of chronic active pelvic inflammatory disease. *Indian J Pathol Microbiol.* 2011;54:141-3. [PubMed]
  10. Chou SC, Wang JS, Tseng HH. Malacoplakia of the ovary, fallopian tube and uterus: a case associated with diabetes mellitus. *Pathol Int.* 2002;52:789-93. [PubMed] [Google Scholar]
  11. Chouairy CJ, Hajal EA, Nehme YA. Xanthogranulomatous oophoritis secondary to talcum powder. Case report and review of the literature. *J Med Liban.* 2012;60:169-72. [PubMed] [Google Scholar]
  12. Singh UR, Revathi G, Gita R. Xanthogranulomatous oophoritis: an unusual complication of typhoid. *J Obstet Gynaecol (Tokyo 1995).* 1995;21:433-6. [PubMed] [Google Scholar]
  13. Singh N, Tripathi R, Mala YM, Arora S. Xanthomatous oophoritis following uterine artery embolisation: successful conservative surgical management with favourable outcome. *BMJ Case Rep.* 2013;2013:bcr2013010184. [PubMed] [Google Scholar]